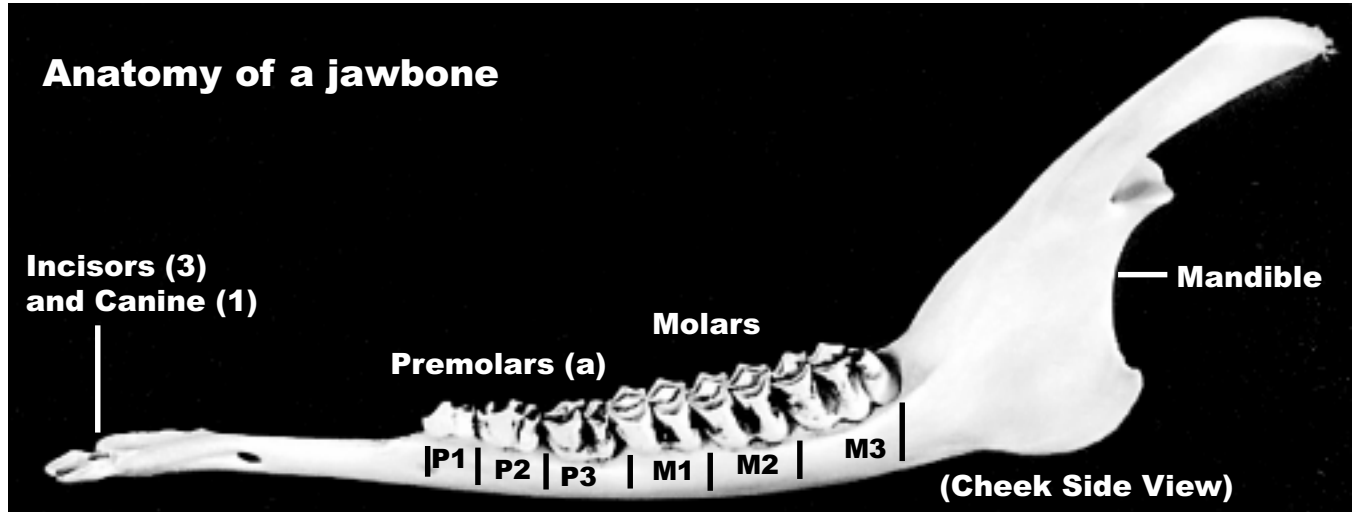
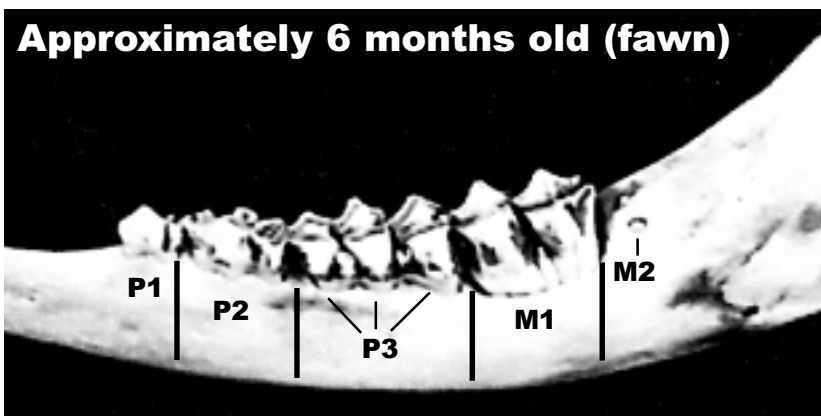

Figure 4.

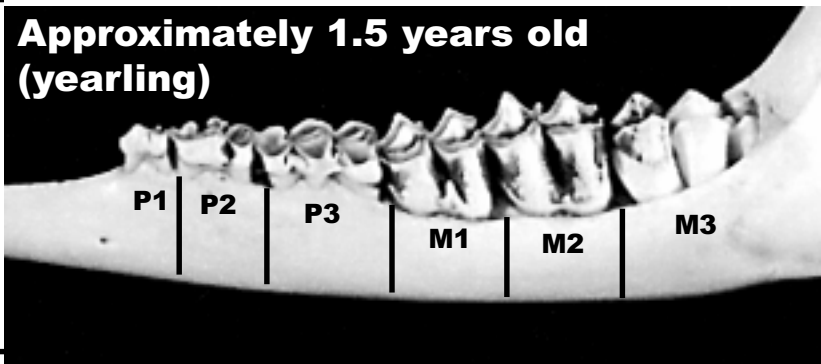
Aging white-tailed deer by tooth eruption and replacement.



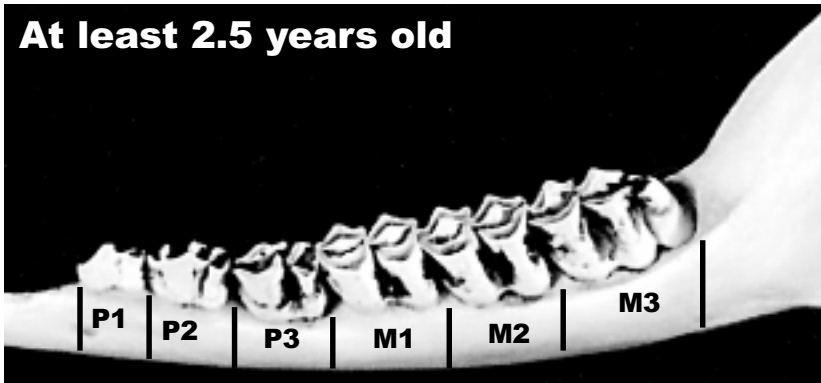
- 1) P3 is a 3-cusped temporary tooth. (b)
- 2) M1 and/or M2 are at some stage of eruption.
- 3) M3 has not yet begun to erupt.



- 1) P3 is usually a 3-cusped temporary tooth (can be a 2-cusped permanent tooth in older yearlings).
- 2) M3 is usually not fully erupted (gum line is usually high on the rear cusp).



- 1) All permanent premolars and molars are fully erupted and showing varying degrees of wear. (c)
- 2) P3 is 2-cusped.



(a) Most scientific sources refer to the premolars as P2, P3 and P4 due to the evolutionary loss of the first premolar.
 (b) Young white-tailed deer have a set of temporary premolars which are replaced with permanent premolars. Molars are always permanent.
 (c) Specific age class estimations for 2.5 years old and beyond are usually based on molar and premolar wear.